

## Lower Incisor Inclination and Symphysis Dimensions in Different Skeletal Patterns

Amna Farrukh<sup>1</sup>, Quarat-ul-Ain Anwar<sup>2</sup>, Sadia Asif Samdani<sup>3</sup>, Samra Bokhari<sup>4</sup>, Ayesha Basit<sup>5</sup>

Received: 04 Oct 2023 / Revised: 22 May 2024 / Accepted: 03 Jun 2024 / Published online: 15 Jul 2024

Copyright © 2024 The Author(s). Published by Foundation University Journal of Dentistry.

**Objectives:** To compare lower incisor inclination and symphysis morphology in Class I, II & III malocclusion individuals.

**Materials and Methods:** In 120 lateral cephalometric images of adults lacking previous orthodontic management, heights of the mandibular symphysis (LH), buccal (LA) & lingual (LP) cortex, as well as inclination, were all measured. Additionally, malocclusion types (Class I, II, & III) were considered. The independent t-test was utilized to evaluate differences in lower incisor location and symphysis dimensions. A  $p$ -value  $\leq 0.05$  was considered as significant. Data analysis was done using SPSS-26.

**Results:** The sagittal malocclusion groups differed significantly in terms of Incisor Mandibular Plane Angle (IMPA) and symphysis size. Because the lower incisor apex in Class III individuals was near the buccal cortex, the value of LA was lower & LH was higher. Because the lower incisor apex of Class II individuals was close to the lingual cortex, their LP value decreased, and their LH value increased.

**Conclusion:** The sagittal malocclusion groups differed significantly in terms of IMPA and symphysis size. Because the lower incisor apex in Class III individuals was near to buccal cortex, the value of LA was lower & LP was higher. Because the lower incisor apex of Class II patients was close to the lingual cortex, their LP value decreased, and their LH value increased.

**Keywords:** Lower Incisor Angulation, Mandibular Symphysis, Morphology

<sup>1</sup>Assistant Professor, <sup>5</sup>Associate Professor, Department of Orthodontics, Hamdard College of Medicine and Dentistry, Karachi, Pakistan

<sup>2</sup>Consultant Orthodontist, Department of Orthodontics, Altamash Institute of Dental Medicine, Karachi, Pakistan

<sup>3</sup>Assistant Professor, Department of Orthodontics, Isra Dental College, Hyderabad, Pakistan

<sup>4</sup>Senior Registrar, National Institute of Child Health, Karachi, Pakistan

**Corresponding author:** Quarat-ul-Ain Anwar, Altamash Institute of Dental Medicine, Karachi, Pakistan.

Email: quarat\_a@hotmail.com

This work is licensed under the Creative Commons Attribution-NonCommercial 4.0 International License. To view a copy of this license, visit <https://creativecommons.org/licenses/by-nc/4.0/>

All copyrights © are reserved with The Author(s). FUJD is an open-access peer-reviewed journal; which permits use, sharing, adaptation, distribution and reproduction in any medium or format, as long as you give appropriate credit to the original author(s) and the source, provide a link to the Creative Commons licence, and indicate if changes were made. FUJD does not allow the commercial use of any published article. All articles published represent the view of the authors and do not reflect the official policy of FUJD.

### How to cite this Article:

Farrukh A, Anwar QA, Samdani SA, Bokhari S, Basit A. Lower Incisor Inclination and Symphysis Dimensions in Different Skeletal Patterns. Found Univ J Dent. 2024;4(2):3-8

### INTRODUCTION

It is evident that the dentofacial composite possesses a compensation system that works to maintain a balanced & proportionate facial structure. The remaining craniofacial tissues react to cover up deviations in

either basal bone's typical growth pattern, whether it be maxilla or mandible.<sup>1</sup> In an effort to create a normal incisor relationship, dental compensation conceals Anteroposterior (AP) and vertical basal bone discrepancies.<sup>2,3</sup>

Holdaway (1956) was the first to suggest a compensation mechanism related to the skeletal Class II apical base for an adequate face balance.<sup>4</sup> The relative tilting of the upper & lower incisors results in this relationship. According to Goldsman (1959), the dentofacial complex possesses compensating or balancing property that maintains general synchronization & proportions of facial patterns.<sup>5</sup> To create a normal incisor relationship, Jacobson (1974) suggested that dento-alveolar compensation serves to conceal AP & vertical basal bone anomalies.<sup>6</sup>

The proportions of the alveolus are changed to conceal AP & vertical basal bone differences when either basal bone diverges from its predicted growth pattern.<sup>7</sup> The cortical indices of the alveolus at the incisor apex might be thought of as “orthodontic walls” since they define anatomical boundaries.<sup>8</sup> Which individuals can be effectively treated with therapy alone, who also need surgery, is a question that emerges. In addition to aesthetics, orthodontists must consider whether there is enough room for orthodontic tooth movement to rectify malocclusion with little iatrogenic tissue loss. The orthodontic walls must be considered when designing a treatment plan since they act as a barrier to tooth movement and a potential hotbed for adverse consequences as well. The borderline condition is classified as “orthodontic” or “surgical-orthodontic” if this unfavourable consequence occurs.<sup>9-11</sup>

Our current study's objective was to examine lower incisor dentoalveolar compensation in individuals with Class II & Class III malocclusions using a straightforward, visualized treatment objective. This will enable us to assess whether there is enough alveolar bone for the incisors to move safely and repair anteroposterior skeletal abnormalities.

## MATERIALS AND METHODS

This descriptive cross-sectional study was carried out over six months (January 2022 to June 2022) at Hamdard College of Medicine & Dentistry after the approval of the institution's Research Ethics Committee (NO ERC/BDS/016/2022). After obtaining written informed consent, a total of 120 patients with skeletal malocclusion who met the eligibility criteria were enrolled in our study via a non-probability sampling technique. The inclusion criterion was patients aged between the ages of 18 and 30 with a full dentition & no prior orthodontic treatment. Patients with syndromic

conditions, prior orthodontic or maxillofacial surgery, craniofacial abnormalities, or root resorption were excluded.

OPENEPI calculator sample was used to calculate the sample size. The sample size was calculated by using the prevalence of malocclusion i.e. 93%<sup>12</sup>, 5% margin of error, and 95% confidence interval. The calculated sample size was 101 but we included 120 patients as we were able to collect 120 samples during the study period to further increase the strength of the study.

The included patients' lateral cephalometric X-rays were acquired and examined. Class I, II, & III malocclusion participants provided 30 X-rays each.

Class I, Class II & III Subjects:

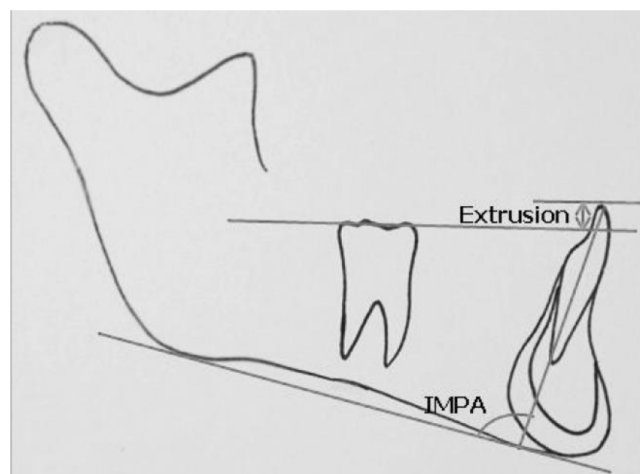
For the sagittal classification of malocclusions, an ANB angle was adopted.

Class I (control group): optimum overjet & overbite, ANB =  $2^{\circ} \pm 2^{\circ}$ .

The subjects for Class II - Class II Div 1 were chosen, ANB =  $>4^{\circ}$

ANB  $<0^{\circ}$  with edge-to-edge incisor relation for Class III.

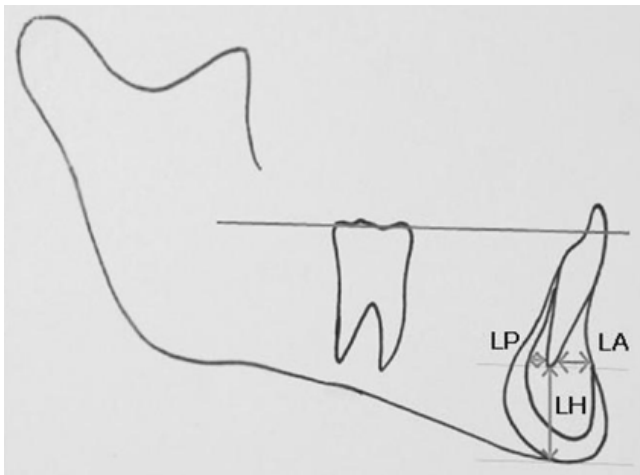All lateral images were taken from the similar digital center to prevent magnification blunder. The same surveyor completed all manual tracings with lead acetate paper & sharp pencil.



**Figure 1: The position of the lower incisor: IMPA and extrusion.**

The incisor-mandibular plane angle (IMPA), which is the angle between the lower incisor's long axis & mandibular plane, was calculated.

Symphysis Dimensions (Figure 2)



**Figure 2: The dimensions of the symphysis: LP, LA, and LH.**

LP: Bone that is lingually posterior to mandibular incisor apex. lingual cortical limit to the apex of the mandibular central incisor along the plane parallel to the occlusal plane traced across the apex.

LA: Bone that is front of mandibular incisor apex (labial). A line traced from the apex of the mandibular central incisor along a plane parallel to the occlusal plane extends to the limit of the labial cortex.

LH: inferior mandibular incisor apical bone. The smallest distance that may be traversed by a line perpendicular is drawn to the occlusal plane from the apex of the mandibular incisor to the lowest point of the symphysis.

For intra-rater reliability complete cephalometric analysis were repeated for 20 randomly chosen radiographs. The business was controlled through strict compliance with inclusion/exclusion criteria. The Class II & Class III participants' measurements of specified dimensions were compared to same of Class I individuals who served as a control group. The independent t-test was used to evaluate differences in the mandibular plane, lower incisor location, & symphysis dimensions. P-values between 0.05 & less were considered as important.

**RESULTS**

Table 1 summarises the comparison of IMPA amongst 3 groups. It demonstrates that class II subjects have an increased IMPA, while class III subjects have lower IMPA. Table 2 compares the dimension of symphysis among all 3 groups & significant differences were found.

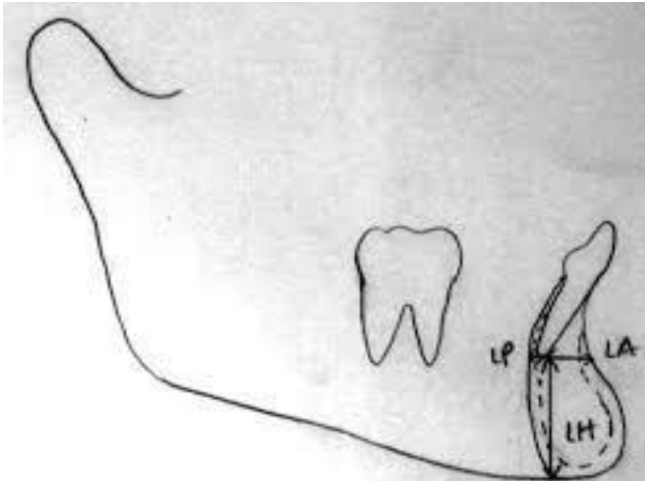
**Table 1: Mean antero-posterior and vertical skeletal measurements**

Parameter	Class-I	Class-II	Class-III	p-values		
				Class I versus Class II	Class I versus Class III	Class II versus Class III
IMPA	91±4.1	104±4.2	87.6±3.0	0.000	0.000	0.000

**Table 2: The comparison of symphyseal dimensions across three study groups**

Parameters	Class-I	Class-II	Class-III	p-values		
				Class I versus Class II	Class I versus Class III	Class II versus Class III
LH (mm)	19±0.7	23±0.6	22±0.4	0.000	0.000	0.000
LP (mm)	3.7±0.2	2.2±0.2	4.5±0.4	0.000	0.000	0.000
LA (mm)	3.9±0.1	4.9±0.1	2.9±0.2	0.000	0.000	0.000

## Class II Subjects (Figure 3)



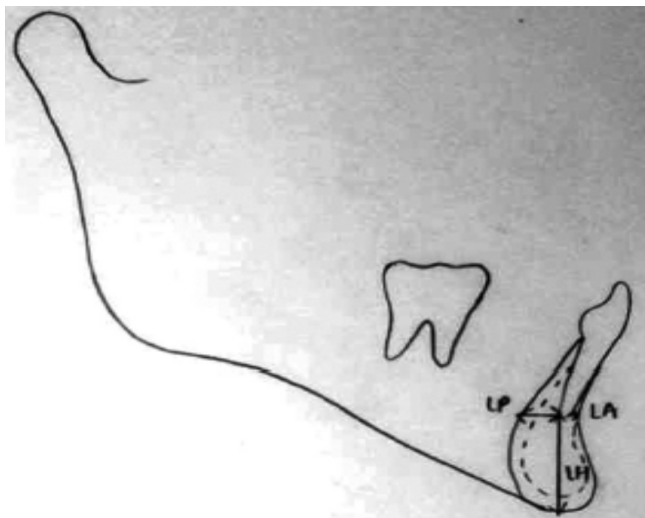
**Figure 3: In Class II subjects, with proclined incisor, the apex nears the lingual cortex**

Component 1: IMPA & LA, the bone amount among the incisor's apex & buccal cortex increases with incisor proclination. LA's value decreases as the value of IMPA does.

Component 2: IMPA & LP, with increment in IMPA, LP value declined.

Component 3: LH, this changeable concludes extrusion of the incisor. It's greater in Class II individuals in comparison to Class I.

## Class III Subjects (Figure 4)



**Figure 4. In Class III subjects, with a retroclined incisor, the apex nears the buccal cortex**

In Class III subjects, with retroclined incisors, the

apex approximates the buccal cortex.

Component 1: IMPA & LA, more ratiocination of incisor, bone amount among apex & buccal cortex.

Component 2: IMPA LP, with the decline of IMPA, LP value increased.

Component 3: LH was greater in Class III individuals in comparison to Class I.

**DISCUSSION**

Class I, II, & III skeletal malocclusions were studied by Handelman. All individuals with malocclusions & lengthy facial structures as well as Class III with normal features showed a decrease in alveolar width. However, sample sizes were small & heterogeneous<sup>13</sup> when the patients were divided into nine subgroups. The relationship among alveolar bone & movement of incisors with respect to vertical & sagittal skeletal structure has been studied in a few additional studies than Handelman's. Small and varied sample sizes were used.<sup>14-17</sup>

Molina-Berlanga N et al, considered class I and III individuals, also found a negative correlation of LA in Class III similar to our study. Because class III individuals have lower incisor's apex close to the buccal cortex.<sup>9</sup>

In a previous study, it was discovered that the amount of bone in the incisor's apex & buccal cortex increased with incisor proclination in Class II participants. LA's value decreases as the value of IMPA does.<sup>18</sup> The same results were seen in our study.

Except for a study by Maniyar et al., where major variations were discovered about symphyseal dimensions between Class I & Class II samples, Class I & Class III samples, & Class II & Class III samples,<sup>18</sup> Class III subjects had previously been evaluated separately in related publications. These outcomes matched what the present study discovered.

3 Dimension-Cone-Beam Computed Tomography (CBCT) is being used by several studies to investigate how lower incisor proclination affects the morphology of the alveolar bone.<sup>15</sup> Without a doubt, future comparisons between our findings and information gleaned from 3D imaging will be necessary.

**CONCLUSION**

The sagittal malocclusion groups differed significantly



in terms of IMPA and symphysis size. Because the lower incisor apex in Class III individuals was near the buccal cortex, the value of LA was lower & LP was higher. Because the lower incisor apex of Class II patients was close to the lingual cortex, their LP value decreased, and their LH value increased.

#### DISCLAIMER

None to declare.

#### CONFLICT OF INTEREST

There is no conflict of interest among the authors.

#### ETHICAL STATEMENT

Ethical approval was taken from Research Ethics Committee of Hamdard College of Medicine & Dentistry Karachi (Ref: ERC/BDS/016/2022).

#### FUNDING DISCLOSURE

The author(s) received no financial support for the research, authorship, and/or publication of this article.

#### AUTHORS CONTRIBUTION

Conception and design of the study: A. Farrukh

Acquisition of data: S.A Samdani, S. Bokhari

Analysis and interpretation of data: Q. Anwar, A. Basit

Drafting of the manuscript: A. Farrukh, Q. Anwar

Critical review of the manuscript: A. Farrukh, Q. Anwar

Approval of the final version of the manuscript to be published: A. Farrukh, Q. Anwar, S.A Samdani, S. Bokhari, A. Basit

#### REFERENCES

- Marghalani HY, Guan G, Hyun P, Tabbaa S, Linjawi AI, Al-Jewair T. Relationship between mandibular symphysis dimensions and skeletal pattern in adults. *Folia Morphol.* 2022;81(2):464-71.
- Foosiri P, Mahatumarat K, Panmekiate S. Relationship between mandibular symphysis dimensions and mandibular anterior alveolar bone thickness as assessed with cone-beam computed tomography. *Dental Press J Orthod.* 2018 ;23(1):54-62.
- Khan MY, Kishore MS, Bukhari SA, Rachala MR, Sashidhar NR. Alveolar and skeletal chin dimensions are associated with lower facial height among different divergent patterns. *J Clin Diagn Res.* 2016;10(5):75-80.
- Holdaway RA. Changes in relationship of points A and B during orthodontic treatment. *Am J Orthod.* 1956 ;42(3):176-93.
- Goldsman S. The variations in skeletal and denture patterns in excellent adult facial types. *Angle Orthod.* 1959;29(2):63-92.
- Jacobson A. The "Wits" appraisal of jaw disharmony. *Am J Orthod.* 1975 ;67(2):125-38.
- Ahn MS, Shin SM, Yamaguchi T, Maki K, Wu TJ, Ko CC, et al. Relationship between the maxillofacial skeletal pattern and the morphology of the mandibular symphysis: Structural equation modeling. *Korean J Orthod.* 2019;49(3):170-80.
- Linjawi AI, Afify AR, Baeshen HA, Birkhed D, Zawawi KH. Mandibular symphysis dimensions in different sagittal and vertical skeletal relationships. *Saudi J Biol Sci.* 2021;28(1):280-5.
- Molina-Berlanga N, Llopis-Perez J, Flores-Mir C, Puigdollers A. Lower incisor dentoalveolar compensation and symphysis dimensions among Class I and III malocclusion patients with different facial vertical skeletal patterns. *Angle Orthod.* 2013 ;83(6):948-55.
- Jabbar A, Nazir M, Mushtaq M, Khoro R, Ghouri MQ. Association of Anterior Alveolar Dimensions with Different Sagittal Jaw Relationships. *Ann Pak Inst Med Sci.* 2022 ;18(3):252-6.
- Islam ZU, Shaikh AJ, Fida M. Dentoalveolar heights in vertical and sagittal facial patterns. *JCPSP.* 2016;26(09):753-7.
- Cenzato N, Nobili A, Maspero C. Prevalence of dental malocclusions in different geographical areas: Scoping review. *Dent. J.* 2021;9(10):117.
- Handelman CS. The anterior alveolus: its importance in limiting orthodontic treatment and its influence on the occurrence of iatrogenic sequelae. *Angle Orthod.* 1996;66(2):95-110.
- Chung CJ, Jung S, Baik HS. Morphological characteristics of the symphyseal region in adult skeletal Class III crossbite and openbite malocclusions. *Angle Orthod.* 2008;78(1):38-43.
- Troy BA, Shanker S, Fields HW, Vig K, Johnston W. Comparison of incisor inclination in patients with Class III malocclusion treated with



- 
- orthognathic surgery or orthodontic camouflage. *Am J Orthod Dentofacial Orthop.* 2009 ;135(2):146-e1.
16. Ishikawa H, Nakamura S, Iwasaki H, Kitazawa S, Tsukada H, Sato Y. Dentoalveolar compensation related to variations in sagittal jaw relationships. *Angle Orthod.* 1999;69(6):534-8.
17. Tang N, Zhao ZH, Liao CH, Zhao MY. Morphological characteristics of mandibular symphysis in adult skeletal class II and class III malocclusions with abnormal vertical skeletal patterns. *Hua Xi Kou Qiang Yi Xue Za Zhi.* 2010;28(4):395-8.
18. Maniyar M, Kalia A, Hegde A, Gautam RG, Mirdehghan N. Lower incisor dentoalveolar compensation and symphysis dimensions in class II and class III patients. *Int J Dent Med Spec.* 2014;1(2):20-4.
-